

Experimental procedures using animal models employing stereotaxic ablation methods targeting the nucleus accumbens (NAcc)

Procedimientos experimentales con modelos animales mediante ablación estereotóxica dirigida al núcleo accumbens (NAcc)

Luciana Canabarro^{1*} 

Raphael Vinícius Gonzaga Vieira² 

Vitória Bernal Cavalcanti³ 

Paulo Henrique Pires de Aguiar^{1,2,3,4} 

ABSTRACT

Introduction: Stereotaxic ablation is widely used in animal models to create precise lesions in specific brain regions. This approach allows for a detailed study of the functions of the lesioned areas and their behavioral, physiological, and neurochemical implications.

Objective: In this study, bilateral ablation of the nucleus accumbens (NAcc) was performed in Wistar rats to investigate the behavioral and neurophysiological effects of functional removal of this region. **Methods:** Surgery was conducted using the EFF-331 stereotaxic device, with anatomical coordinates based on the Paxinos and Franklin atlas. The lesion was made using radiofrequency applied via a 4 mm needle developed specifically for this procedure, under general anesthesia combined with local anesthesia. Following the procedure, the animals were monitored for 28 days and received appropriate analgesia to ensure postoperative well-being. **Results and discussion:** The results indicated that the technique enabled precise and localized lesions in the NAcc, with minimal interference with adjacent structures, ensuring reproducibility and strict control of experimental variables. Behavioral analysis demonstrated significant alterations related to NAcc functions, contributing to the understanding of the neurobiological mechanisms involved in motivated behaviors and emotional states. The study highlights the importance of rigorous ethical and methodological care in the use of animal models and recommends complementing behavioral data with histological and neurochemical analyses to confirm the extent and specificity of the lesions, especially considering individual anatomical variations and post-lesion neuroplastic responses. **Conclusion:** the bilateral ablation of the NAcc via stereotaxy proved to be a safe, effective, and reproducible procedure with great potential for neurofunctional investigations and advancing the understanding of neural circuits related to reward, motivation, and emotional regulation.

Keywords: stereotaxy; nucleus accumbens; brain ablation.

RESUMEN

Introducción: La ablación estereotóxica se utiliza ampliamente en modelos animales para crear lesiones precisas en regiones cerebrales específicas. Este enfoque permite un estudio detallado de las funciones de las áreas lesionadas y sus implicaciones conductuales, fisiológicas y neuroquímicas. **Objetivo:** En este estudio, se realizó una ablación bilateral del núcleo accumbens (NAcc) en ratas Wistar para investigar los efectos conductuales y neurofisiológicos de la eliminación funcional de esta región. **Métodos:** La cirugía se llevó a cabo utilizando el dispositivo estereotáxico EFF-331, con coordenadas anatómicas basadas en el atlas de Paxinos y Franklin. La lesión fue inducida mediante radiofrecuencia aplicada a través de una aguja de 4 mm desarrollada específicamente para este procedimiento, bajo

¹Instituto de Assistência Médica ao Servidor Público Estadual – IAMSPE, São Paulo, SP, Brasil.

²Hospital Santa Paula, Departamento de Neurocirurgia, São Paulo, SP, Brasil.

³Pontifícia Universidade Católica de São Paulo – PUC-SP, Faculdade de Ciências Médicas e da Saúde, São Paulo, SP, Brasil.

⁴Centro Universitário Faculdade de Medicina do ABC – FMABC, Santo André, SP, Brasil.

Received May 21, 2025

Accepted June 2, 2025



This is an Open Access article distributed under the terms of the [Creative Commons Attribution](https://creativecommons.org/licenses/by/4.0/) license (<https://creativecommons.org/licenses/by/4.0/>), which permits unrestricted use, distribution, and reproduction in any medium, provided the original work is properly cited.

anestesia general combinada con anestesia local. Tras el procedimiento, los animales fueron monitoreados durante 28 días y recibieron analgesia adecuada para garantizar el bienestar posoperatorio. **Resultados y Discusión:** Los resultados indicaron que la técnica permitió lesiones precisas y localizadas en el NAcc, con mínima interferencia en estructuras adyacentes, asegurando la reproducibilidad y el control riguroso de las variables experimentales. El análisis conductual demostró alteraciones significativas relacionadas con las funciones del NAcc, lo que contribuye a la comprensión de los mecanismos neurobiológicos involucrados en conductas motivadas y estados emocionales. El estudio resalta la importancia del cuidado ético y metodológico riguroso en el uso de modelos animales, y recomienda complementar los datos conductuales con análisis histológicos y neuroquímicos para confirmar la extensión y especificidad de las lesiones, especialmente considerando las variaciones anatómicas individuales y las respuestas neuroplásticas posteriores a la lesión. **Conclusión:** la ablación bilateral del NAcc mediante estereotaxia demostró ser un procedimiento seguro, eficaz y reproducible, con gran potencial para investigaciones neurofuncionales y para el avance en la comprensión de los circuitos neurales relacionados con la recompensa, la motivación y la regulación emocional.

Palabras clave: estereotaxia; núcleo accumbens; ablación cerebral.

1 INTRODUCTION

Experimental procedures using animal models and stereotaxic ablation methods are widely employed, as they allow for the selective lesioning of specific brain regions. This approach enables the investigation of the functions of these areas and the behavioral, physiological, and neurochemical implications resulting from the targeted removal or damage of specific neural structures¹.

Stereotaxy is an approach that employs a highly precise stereotaxic apparatus, based on three-dimensional Cartesian coordinates and specific anatomical landmarks, ensuring accurate localization of targets within the body, particularly in the central nervous system. This technique allows for precise access to target structures while minimizing damage to adjacent tissues, thereby enhancing the safety and efficacy of the procedure, in addition to offering high precision and reproducibility^{1,2}.

Due to its precision and minimally invasive nature, stereotaxy is widely used in functional neurosurgery, biopsies, radiosurgery, and the treatment of various neurological disorders³.

This method can also be employed to investigate the effects of ablation on other regions, enabling the analysis of potential functional, structural, or connectivity changes resulting from the specific lesion⁴.

The choice of this model is justified by the functional importance of the nucleus accumbens (NAcc), a central structure in the neural circuits involved in mediating complex behavioral functions. The NAcc plays a key role in regulating processes related to reward,

motivation, and emotional control, acting as an integration point between dopaminergic, limbic, and cortical systems⁴.

Its relevance within these circuits makes it a strategic target for investigations aiming to understand the neurobiological mechanisms underlying motivated behaviors and emotional states⁵.

Accordingly, the study aimed to deepen the understanding of the neurophysiological mechanisms involved in the behavioral responses associated with this brain region. The procedure was conducted in accordance with strict ethical standards and was approved by the Institutional Animal Care and Use Committee (CEUA - Comitê de Ética em Pesquisa no Uso de Animais) of FCMS/PUC-SP under protocol number 2020/126.

2 OBJECTIVE

This study aims to describe the stereotaxically guided bilateral ablation technique of the nucleus accumbens (NAcc) using minimally invasive methods.

3 METHODOLOGY

Forty-eight female Wistar rats, aged between six and eight months and weighing between 250 and 400 grams, were used.

The animals were housed in polypropylene cages (four per cage) under controlled temperature, humidity, and light–dark cycles, with free access to food and water.

The NAcc ablation surgery was performed using a stereotaxic apparatus (EFF-331, Insight Equipment Ltda.®) (Figure 1), following the coordinates obtained from the *The Mouse Brain in Stereotaxic Coordinates* atlas by Paxinos and Franklin (Figure 2).

The coordinates applied were:

- **Capsule lesion:** bregma +2.04 mm (anteroposterior), ± 1.72 mm (mediolateral), +0.90 mm (dorsoventral).
- **Nucleus lesion:** bregma +2.04 mm (anteroposterior), ± 1.64 mm (mediolateral), +1.20 mm (dorsoventral).

The targeted lesion was performed using a radiofrequency device, with a 4 mm diameter needle specifically designed for this purpose and manufactured by Micromar® (Figure 3 – Radiofrequency device), (Figures 4 and 5 – 4 mm diameter radiofrequency needle, Micromar®).

The procedure was performed under general anesthesia using ketamine (90 mg/kg, i.m.) and xylazine (5 mg/kg, i.m.), complemented by local anesthesia with lidocaine (0.4 ml, s.c.).

The surgical procedure consisted of securing the animal's head in the stereotaxic frame.

The incision and skull drilling were performed according to the predetermined coordinates, followed by needle insertion and radiofrequency application (60 °C for 20 seconds) (Figure 6).

The incision was closed using 3-0 nylon sutures. After the surgical procedure, the animals were housed individually for 12 hours to recover and were then returned to the experimental environment, where they remained for an additional 14 days, totaling 28 days of observation.

Analgesia and euthanasia

For analgesia, carprofen (5-15 mg/kg, Rymadil®, Pfizer) was administered preoperatively, and 2% lidocaine gel was applied postoperatively.



Figure 1. Stereotaxic apparatus EFF 331 Single-Tower Stereotaxic Frame (EFF-331).

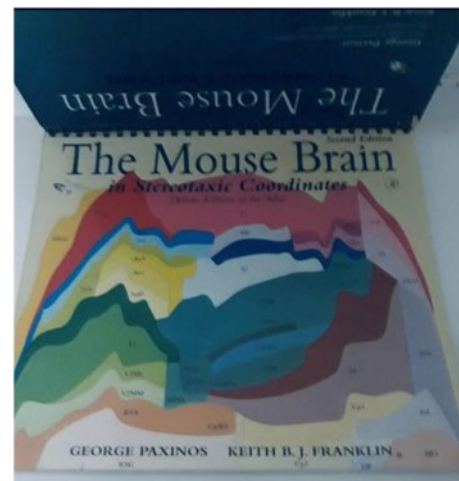


Figure 2. The Mouse Brain in Stereotaxic Coordinates atlas by Paxinos and Franklin.



Figure 3. Radiofrequency device.



Figure 4. (A), (B) 4 mm diameter radiofrequency needle, Micromar®.

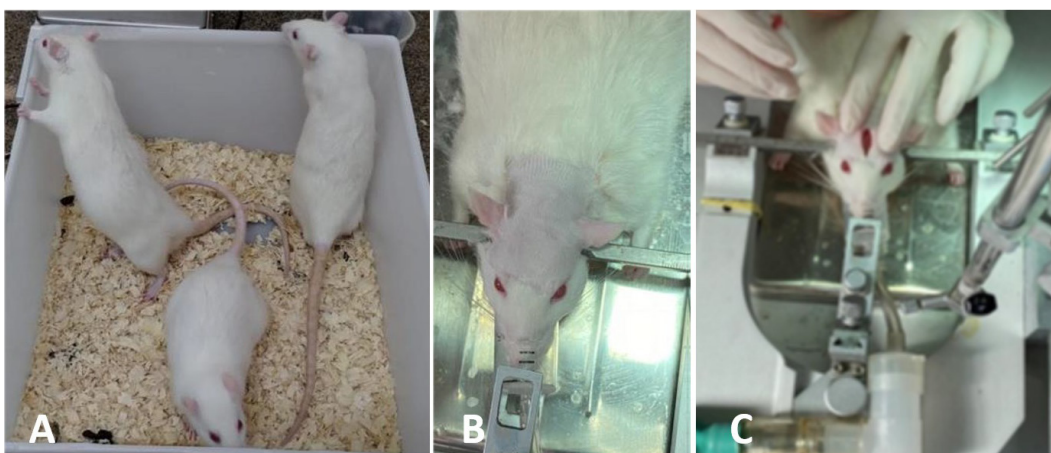


Figure 5. (A) Animals; (B) Anesthetized rat positioned in a stereotaxic apparatus; (C) Incision to expose the skull.

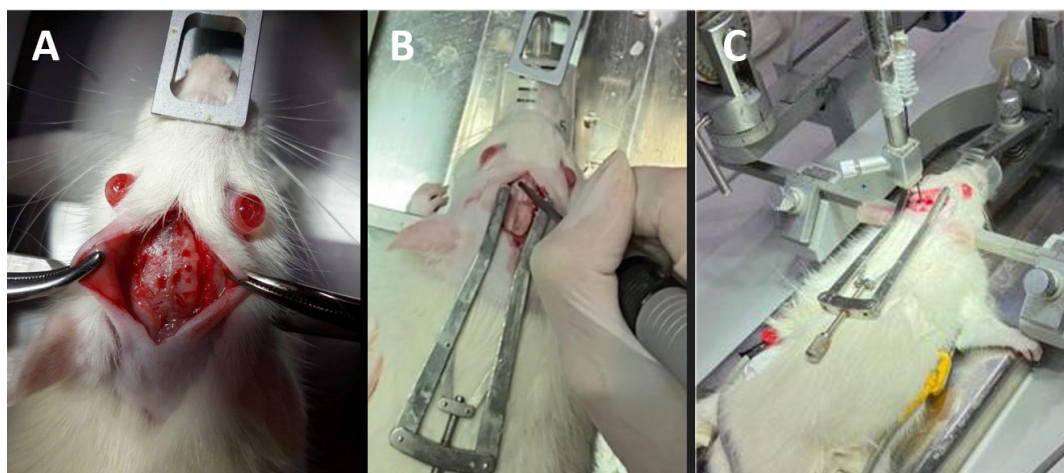


Figure 6. (A) Bregma visualization; (B) Drilling the skull using a saline-cooled dental drill; (C) Radiofrequency ablation with a 4mm needle at 60°C in 20s.

The rats were allowed to recover in order to assess the impact of the ablation. After 28 days, the animals were euthanized by halothane inhalation (5 ml), followed by brain removal. The brains were then stored in 10% formalin for future analysis.

4 DISCUSSION

The stereotactically guided bilateral ablation of the nucleus accumbens (NAcc) proved to be effective and accurate in producing localized lesions, with minimal damage to adjacent structures. This was evidenced by the standardized anatomical coordinates and the use of high-precision equipment, such as the stereotaxic apparatus and the radiofrequency needle⁶.

This method allowed selective access to the target region, ensuring procedural reproducibility and minimizing variables that could compromise the experimental results⁶.

The selection of the NAcc as the target structure proved to be relevant, given its central role in neural circuits related to reward, motivation, and emotional regulation. Ablation of this region allows for the investigation of behavioral changes resulting from the functional loss of its connections, providing insights into the neurobiological mechanisms underlying psychiatric disorders such as substance dependence, depression, and anxiety disorders⁷.

The pre- and postoperative care, including the use of appropriate analgesia and behavioral monitoring during the recovery period, reinforces the ethical and methodological commitment of the research. Additionally, the standardization of observation time and postoperative conditions ensured greater control over behavioral variables associated with the surgical intervention⁸.

Previous studies had already demonstrated the feasibility of the stereotaxic ablation technique in different brain regions, supporting the findings of this study regarding the precision of the approach and the ability to assess the functional effects of the lesion on animal behavior⁸.

However, it is important to note that factors such as individual anatomical variations and possible inflammatory or neuroplastic

processes resulting from the lesion may influence behavioral outcomes. These results should therefore be interpreted with caution and, whenever possible, complemented by histological or neurochemical analyses to confirm the extent and specificity of the lesion.

5 CONCLUSION

The stereotactically guided bilateral ablation of the nucleus accumbens (NAcc) proved to be a safe, precise, and reproducible procedure for selectively lesioning this structure in animal models. This approach enabled the investigation of neurobehavioral effects associated with the functional removal of the NAcc, contributing to the understanding of neural circuits involved in reward, motivation, and emotional regulation. The results reinforce the potential of stereotaxic techniques as an experimental tool for neurofunctional studies, while also emphasizing the importance of strict ethical and methodological standards in the use of animal models.

Future research may further elucidate the adaptive and compensatory mechanisms resulting from the lesion through integration with histological, neurochemical, and neuroimaging analyses.

REFERENCES

1. Martini CS, França WM, Canabarro L, Nakabashi F, Aguiar PHP. Evaluation of weight, caloric intake, and behavior of rats after bilateral ablation of the nucleus accumbens shell. *J Bras Neurocir*. 2021;32(1):15-27. <http://doi.org/10.22290/jbnc.v32i1.1939>.
2. Teixeira MJ, Fonoff E. A brief history of stereotaxy. *Rev Med*. 2004;83(1-2):50-3. <http://doi.org/10.11606/issn.1679-9836.v83i1-2p50-53>.
3. Pittella JEH. Stereotactic biopsy in the diagnosis of brain tumors and non-neoplastic lesions: prescription, accuracy and diagnostic difficulties. *J Bras Patol Med Lab*. 2008;44(5):343-54. <http://doi.org/10.1590/S1676-24442008000500006>.
4. Machado A, Haertel LM. *Neuroanatomia funcional*. 3. ed. São Paulo: Atheneu; 2021. 333 p.

5. Magalhaes MJS, Reis C, Costa AD, et al. The nucleus accumbens and deep brain stimulation: a literature review. *Braz J Neuroanat.* 2017;1(1):1-7.
6. Lamas V, Estévez S, Pernía M, Plaza I, Merchán MA. Stereotactically-guided ablation of the rat auditory cortex, and localization of the lesion in the brain. *J Vis Exp.* 2017;(128):56429. PMID:29053697.
7. Clarkson C, Juárez JM, Merchán MA. Transient downregulation of sound-induced c-Fos protein expression in the inferior colliculus following auditory cortex ablation. *Front Neuroanat.* 2010;4:141. <http://doi.org/10.3389/fnana.2010.00141> PMID:21088696.
8. Lamas V, Estévez S, Pernía M, Plaza I, Merchán MA. Stereotactically-guided ablation of the rat auditory cortex, and localization of the lesion in the brain. *J Vis Exp.* 2017;(128):56429. PMID:29053697.

CORRESPONDING AUTHOR

Luciana Canabarro

E-mail: kanabarro@gmail.com

Funding: none.

Conflict of interests: none.

Ethics Committee Approval: *Institutional Animal Care and Use Committee (CEUA - Comitê de Ética em Pesquisa no Uso de Animais) approval: FCMS/PUC-SP under protocol number 2020/126.*