

# Cranial vault cavernous angioma. Case report and a short review

## *Angioma cavernoso de la calota craneana. Caso clínico y breve reseña*

Fernando Martínez<sup>1,2\*</sup> 

Nicolás Sgarbi<sup>3</sup> 

Francisco Garagorry<sup>4</sup> 

Martín Fernández<sup>1</sup> 

### ABSTRACT

**Introduction:** Cavernous angiomas are relatively common lesions at the bone level, but few cases of this type of lesion have been reported in the cranial vault. **Clinical case:** A 45-year-old man consulted for cranial pain. On palpation, he noticed a lump in the left parietal region. A CT scan of the skull was performed, which showed a lytic lesion at the parietal level. MRI study was performed and resection was proposed, with the diagnosis of "Skull lytic lesion". Complete resection of the lesion was performed with bone margin and the bone defect was replaced with acrylic. The result of the pathological anatomy showed a bony cavernoma. **Discussion and conclusions:** Cavernomas are very rare lesions at the level of cranial bones. Only 7 cases have been reported in the Latin American literature and less than 300 in the world literature. Diagnosis of these lesions is difficult, since lytic lesions of another origin are more frequent. Differential diagnoses include metastasis, lymphoma, aneurysmal bone cyst, sarcomas, intraosseous meningiomas, or dermoid tumors. The ideal treatment is surgery with margin, although in cases of very large or unresectable lesions, pre-surgical embolization and radiotherapy may be considered.

**Keywords:** cavernous angioma; cranial bone tumor; neurosurgery; cranial vault tumor.

### RESUMEN

**Introducción:** Los angiomas cavernosos son lesiones relativamente frecuentes a nivel óseo, pero se han reportado pocos casos de este tipo de lesiones en la calota craneana. **Caso clínico:** Se trata de un varón de 45 años que consultó por dolor craneano. A la palpación, notó una tumoración en la región parietal izquierda. Se realizó TC de cráneo que evidenció una lesión de tipo lítico a nivel parietal. Se completó su estudio con IRM y se planteó resección de la misma con el planteo potencial de lesión de tipo metastásico, por su patrón lítico en imagen. Se hizo resección completa de la lesión con margen óseo y se sustituyó el defecto óseo con placa de acrílico. El resultado de la anatomía patológica evidenció un cavernoma óseo. **Discusión y conclusiones:** Los cavernomas son lesiones muy poco frecuentes a nivel de huesos craneanos. Se han reportado únicamente 7 casos en la literatura latinoamericana y menos de 300 en la literatura mundial. Son lesiones de diagnóstico de descarte, ya que lo habitual es que se planteen lesiones líticas de otro origen. Entre los diagnósticos diferenciales se plantean metástasis, linfoma, quiste óseo aneurismático, sarcomas, meningiomas intraóseos o tumores dermoides. El tratamiento ideal es la cirugía resectiva con margen, aunque en casos de lesiones muy voluminosas o irresecables, puede plantearse la embolización prequirúrgica y la radioterapia.

**Palabras clave:** angioma cavernoso; tumor óseo craneano; neurocirugía; tumor de calota craneana.

<sup>1</sup>Departamento de Neurocirugía, Hospital de Clínicas de Montevideo, Uruguay.

<sup>2</sup>Medicare, Montevideo, Uruguay.

<sup>3</sup>Centro de Alta Tecnología, Mutualista Círculo Católico, Montevideo, Uruguay.

<sup>4</sup>Departamento de Patología, Hospital de Clínicas de Montevideo, Uruguay.

Received May 16, 2025

Accepted May 19, 2025



This is an Open Access article distributed under the terms of the [Creative Commons Attribution](https://creativecommons.org/licenses/by/4.0/) license (<https://creativecommons.org/licenses/by/4.0/>), which permits unrestricted use, distribution, and reproduction in any medium, provided the original work is properly cited.

## 1 INTRODUCTION

Cavernous angiomas (CA) are common vascular malformations that can affect various organs, including the bone.

Bone CA are relatively rare (representing 0.7 to 1% of bone tumors) and those of cranial location are very rare, about 125 cases were reported until the year 2000<sup>1-7</sup>.

Therefore, these are rare tumors in this location, being located with a much higher incidence in the vault than the base of the skull<sup>2</sup>.

The authors report a case of parietal cavernous angioma in an adult and review the topic.

## Clinical case

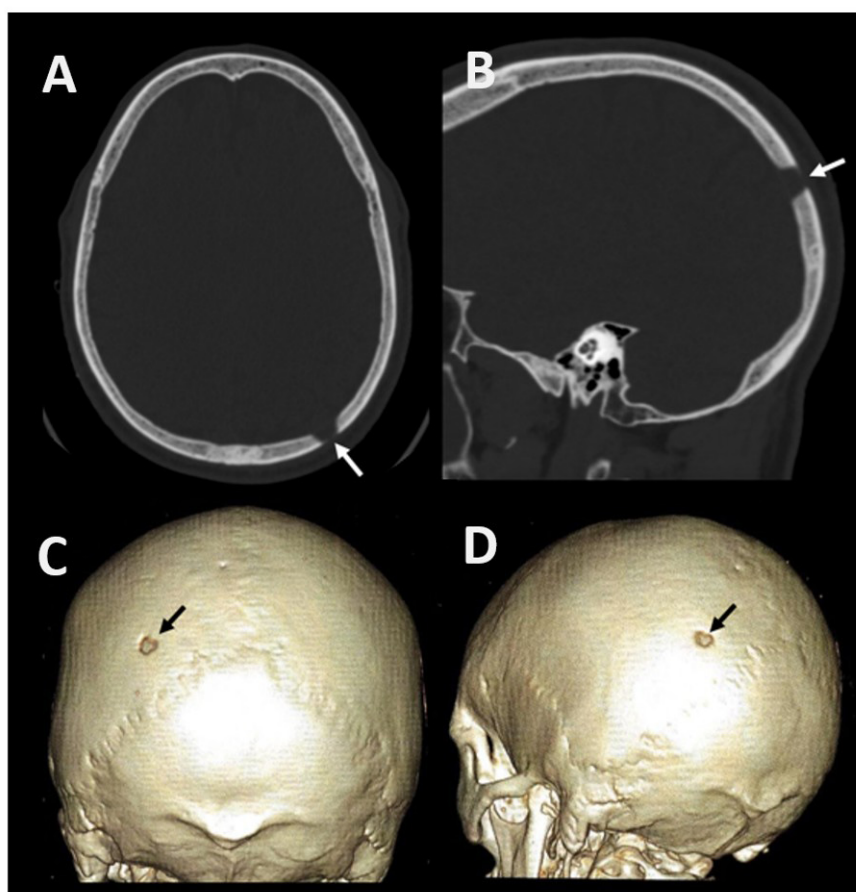
A 45-year-old man consulted for headache. The pain was intense, with a nocturnal component, which woke him up at night.

On examination, he presented a small lump in the right parietal region. It was soft and painful at touch.

The rest of the exam was normal.

Computed tomography (CT) of the skull with 3D reconstructions showed a focal lytic lesion at the parietal level on the left side, with involvement of both cortical, well defined and without neighboring periosteal reaction.

It has a central component of soft tissue density without clear intracranial extension in this technique (Figure 1)



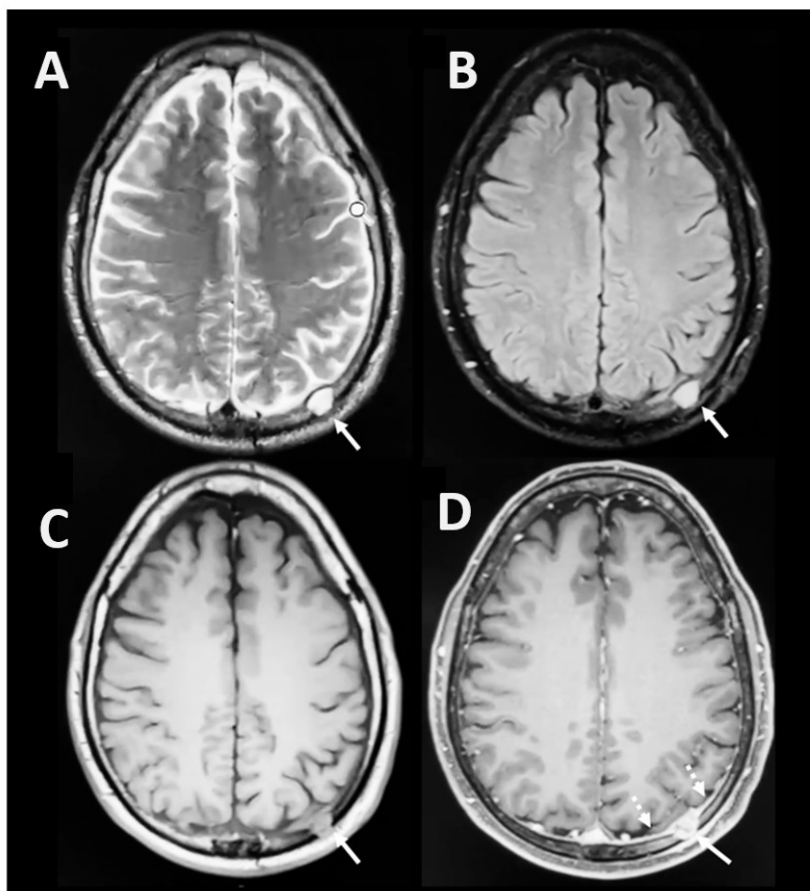
**Figure 1.** Computed tomography. It can be seen a lytic lesion at the left parietal level with involvement of both cortical (arrows). (A) and (B) images in the axial and sagittal planes, respectively, with bone density window; (C) and (D) 3D reconstructions in volume rendering, back views and side poster mode respectively.

The MRI study confirms the presence of the lesion already observed in CT. It is a lesion with a high signal in T2 and isointense in T1, with intense post-contrast enhancement. In the post-contrast sequence, the presence of dural thickening underlying the lesion is verified (Figure 2).

Surgery of the lesion was performed with diagnostic objective. The patient reported that in the evolution, he noticed a decrease in palpable mass. Due to this clinical fact, it was suggested that it was an eosinophilic granuloma.

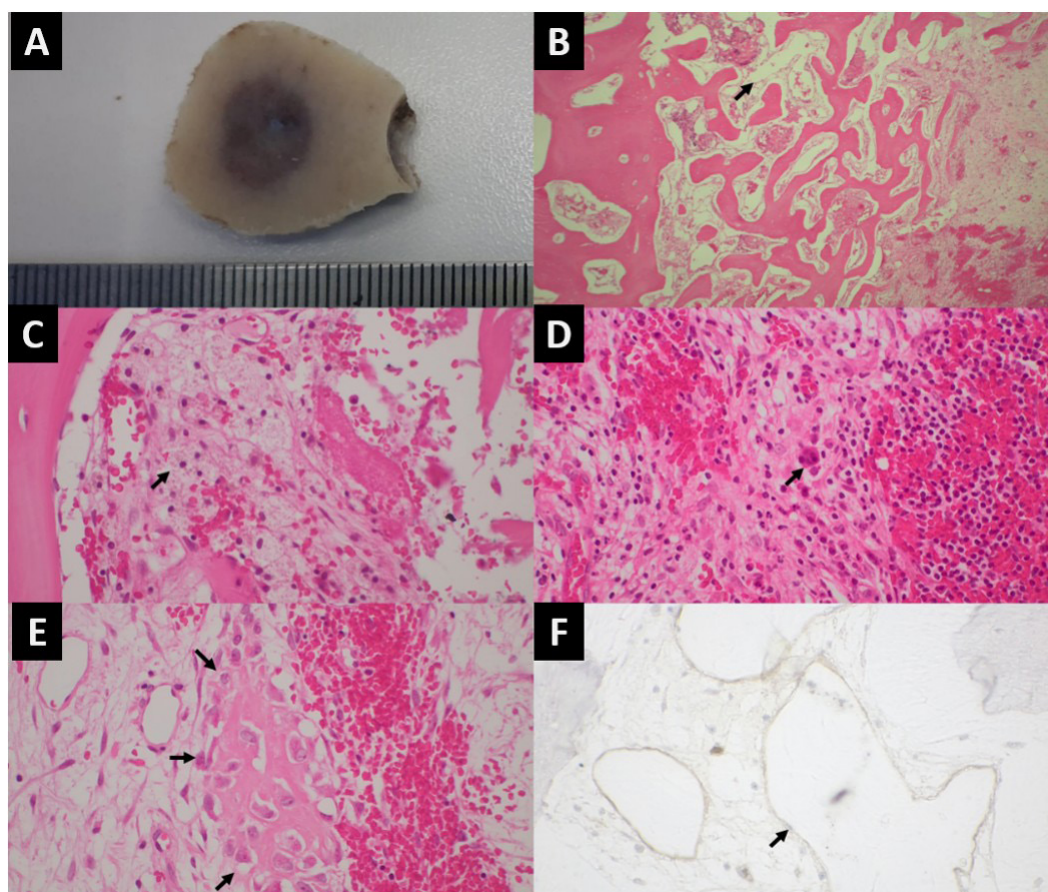
The approach was planned by palpation of the lesion and anatomical repairs (location of the lesion relating to the lambdoid suture). The lesion was recognized and completely resected with margin, repairing the bone defect with surgical acrylic. The evolution was very good, without incidents.

The pathological examination at the macroscopic level (Figure 3A) revealed a relatively well-circumscribed, brownish lesion measuring 11 × 10 mm, involving the diploe and both cortical tables. Histologically, there was evidence of cavernous capillary vessels with interconnected labyrinthine spaces, without cytological atypia (Figure 3B). These findings were accompanied by secondary changes, including a chronic inflammatory infiltrate and fibrosis (Figure 3D), xanthomatous transformation with foamy macrophages (Figure 3C), and a peripheral osteoblastic reaction (Figure 3E). Immunohistochemical analysis demonstrated positivity for CD34 (Figure 3F) and podoplanin in the vascular component, with no aberrant expression of histiocytic markers (CD1a, CD207, S100, BRAF V600E) in the foamy macrophage population. Additionally, the lymphoplasmacytic population displayed a reactive pattern, as evidenced by staining for CD20, CD3, CD138, kappa, lambda, and IgG4.



**Figure 2.** Magnetic Resonance Imaging. Lytic lesion (arrows) at the left parietal level with a high signal in T2 (A) and in FLAIR (B), in T1 (C) isointense with intense enhancement in post-contrast T1 (D). In the post-contrast sequence, dural thickening is evidenced below the lesion with a sign of the “dural tail” (D-dotted arrows).





**Figure 3.** Pathological anatomy (description in the text). (A) Macroscopy; (B-E) H&E; (F) Immunohistochemistry.

## 2 DISCUSSION

The first case reported in the Anglo-Saxon literature of cavernous angioma at the level of the skull bones was carried out by Joseph Toynbee in 1845<sup>6-9</sup>.

In this brief report, the author describes a postmortem case of a large parietal cavernous angioma in a 19-year-old patient.

CA at the level of the bones of the skull are very rare tumors.

## 3 EPIDEMIOLOGY

Cavernous angiomas are common tumors at the bone level, representing up to 1% of them<sup>10,11</sup>. They predominate frankly at

the spinal level, being very rare at the cranial level, where they represent between 0.2 and 1% of cranial bone tumors<sup>10-21</sup>.

Curcio et al.<sup>11</sup> in a systematic review found 151 cases published between 1945 and August 2022, marking their rarity.

They can occur at any age, but their appearance predominates between the second and fourth decades<sup>1,11-13</sup>. In a meta-analysis about 77 cases, the average age of presentation was 32.7 years<sup>2</sup>. Paediatric cases are less than 10% of the total<sup>10,14,15</sup>.

They are more frequent in females with a predominance that varies between 1.4/1, 2/1, 3/1 or 4/1<sup>1,2,4,6,7,15,16</sup>. A report from the 1970s on 25 cases showed a male predominance in a 2:1 ratio<sup>9</sup>.

Characteristically, they are single lesions, although there are some reports that in 5.3 to 15% of cases can be seen multiple lesions<sup>1,11,17-21</sup>. Xu et al.<sup>22</sup> reports only 10 articles about multiple CA.

The vast majority are focal, with very few cases of diffuse or invasive angiomas being described<sup>19</sup>.

Of the cranial cavernous angiomas, the vast majority are located in the skull, with a ratio of 10:1 related to those located at the base of the skull<sup>2</sup>. They can occur in any bone of the skull, being more frequent at the frontal and parietal level<sup>1,2,13,16,17,19</sup>. Then follows in frequency the temporal bone and they are very rare at the occipital level<sup>4,6</sup>. Yang<sup>6</sup> reports that out of 93 reported cases, 44.1% were located in the frontal, 12.9% in temporal and parietal, respectively, 11.8% at the occipital level and 5.4% at the skull base. They are described in other topographies but very rare: sphenoid bone, zygoma, ethmoids, clivus and orbital rim<sup>6,16,21</sup>.

Most reports of cranial cavernous angiomas come from Europe, USA, and East Asia, although this does not necessarily show a higher incidence but simply the greater interest in reporting the cases found<sup>17,19</sup>.

Likewise, the bibliographic search in Anglo-Saxon databases (Pubmed) also imposes a bias on the articles consulted.

We performed a search in Latin databases (Lilacs, Scielo) using Deepseek AI, between 1990 and 2025, finding only 7 cases of cavernous angiomas of the cranial vault (Table 1).

### *Origin and development*

The origin of the CA remains unclear, but cavernomas of this topography develop from pathological vessels of the diploic space and receive arterioles from branches of the external carotid: superficial temporal and middle meningeal arteries, mainly<sup>11,22-29</sup>. Some researchers have proposed that it may be a hereditary disease, associated with a mutation in the KRIT1/CCM1 gene, which encodes a protein that affects the structure and function of endothelial cells and correlates with their pathogenic mechanisms<sup>17</sup>. This gene guides the normal development of vessels and its alteration may be at the base of the abnormal development of cavernomas, as it affects the adhesion and migration of vascular cells<sup>29</sup>. However, it is not clear that there is a specific genetic alteration in cranial cavernomas.

Recent studies show that head trauma and ionizing radiation - particularly stereotactic radiosurgery treatment for brain tumors - may be linked to the development of cavernous angiomas<sup>7</sup>. All these factors are associated with endothelial proliferation, so it can play a role in the development of these malformations. Subsequently, its slow and progressive growth is due to intralesional bleeding.

It is interesting that pediatric cases are very rare and even less frequent in children under one year of age. The skull of children does not have a significant diploic space until 30 months of age,

**Table 1.** Cranial vault cavernous angiomas published between 1990-2025 in Latin American databases. The search was made using Deepseek AI

Title	Journal	Year	Country	Database/DOI
Hemangioma cavernoso de calota craneana: relato de caso	Revista Brasileira de Neurocirurgia	2015	Brasil	SciELO
Cavernous hemangioma of the skull: A case report and literature review	Cirugía y Cirujanos (SciELO México)	2018	México	SciELO
Hemangioma cavernoso óseo en cráneo: diagnóstico por imágenes	Revista Argentina de Radiología	2012	Argentina	LILACS
Hemangioma cavernoso de calota: presentación atípica en un adulto mayor	Revista Chilena de Neurocirugía	2020	Chile	SciELO
Tumores vasculares de cráneo: serie de casos en un hospital de referencia	Revista Colombiana de Cancerología	2019	Colombia	LILACS
Cavernous hemangioma of the skull: Surgical management and review	Brazilian Neurosurgery (SciELO)	2021	Brasil	DOI
Hemangioma cavernoso primario de hueso parietal: reporte de caso	Neurocirugía (Perú)	2017	Perú	LILACS

so the alteration in these cases could begin in the intrauterine period in some patients and in early childhood in others<sup>29</sup>.

### *Pathology*

Hemangiomas are benign vascular tumors composed of blood vessels<sup>30</sup>. Macroscopically, they typically present as well-circumscribed, reddish-brown lesions within the bone, although they may sometimes induce inflammatory changes and sclerosis, rendering them less conspicuous. Histologically, they consist of aggregates of thin-walled blood vessels, with lumens that may be dilated and anastomosing (cavernous hemangiomas) or small and capillary-like (capillary hemangiomas)<sup>31</sup>. The endothelial cells are arranged in a single layer, lacking cytological atypia, proliferative activity, or necrosis<sup>32</sup>. Secondary changes such as hemorrhage, chronic xanthomatous inflammatory infiltrates, or reactive endothelial proliferations due to recanalization are not uncommon, potentially complicating the diagnosis. In such cases, immunohistochemical studies can aid in excluding lymphoid, meningothelial, or histiocytic neoplasms<sup>33</sup>.

### *Clinical presentation*

The clinical presentation of cranial cavernous angiomas is usually a palpable mass, which slowly increases in size, producing aesthetic defects<sup>1,4,11,34-36</sup>. Growth can occur in months or years.

They can cause diffuse (headache) or local pain, although they can also grow without causing any pain or discomfort<sup>11,29,35</sup>. Exceptionally, they cause neurological deficit due to compressive effect when they have a very voluminous intracranial growth<sup>6</sup>. Mild changes in color have been described in some patients in the skin above the tumor, which is red or purplish<sup>7,9</sup>.

Therefore, its clinical presentation is nonspecific.

In our case, the patient's report of very slow increase in size of the lesion with subsequent partial regression was striking.

## 4 IMAGING

Imaging studies are essential in the evaluation of cranial vault lesions, with CT and MRI being complementary techniques due to their different contributions.

In the case of a focal lesion of the cranial vault, the differential diagnoses are multiple and, in many cases, complex.

To make an adequate differential diagnosis, it is essential to take into consideration different specific findings about the lesion: location and extension, relationship with the sutures, whether it is solitary or multiple, specific characteristics (lytic, blastic or mixed), periosteal reaction, associated dural involvement, among others<sup>37</sup>.

Although these various signs are important, they allow us to establish patterns of aggressiveness, but in many cases they do not allow us to differentiate between benign or malignant lesions<sup>37</sup>.

CA are incidentally diagnosed in most cases when an imaging study is performed, usually to unrelated symptoms<sup>38</sup>.

They are solitary, focal, usually well-defined, intradiploic, expansive lesions, and can variably affect both cortical tables of the cranial vault depending on their size.

Involvement of the internal table may be associated with dural involvement, with thickening of this layer of variable extension and which translates as a focal area of dural enhancement underlying the lesion - like a "dural tail" sign.

In CT, as in conventional radiology studies, CAs are usually seen as hypodense, radiolucent lesions, which configure the classic lytic pattern, with an expansive growth pattern<sup>37</sup>.

In MRI, the most frequent findings are the combination of low-signal and high-T1 foci, due to the combination of fat and lesional tissue, high T2 signal, and heterogeneous enhancement with contrast medium<sup>39,40</sup>.

The signs of "honeycomb" and "sunrays" have been described by the appearance of the central sector of the lesion as a typical finding when dealing with bulky lesions, although this finding is not pathognomonic<sup>41</sup>.

Differential imaging diagnoses are diverse and include other lesions that present with a lytic pattern.

The most relevant of these diagnoses in an adult patient is the possibility of lytic bone metastasis, especially due to the prognostic and therapeutic implications.

Lytic bone metastases are the most frequent and their appearance may be identical to CAs, although their pattern of involvement is usually more destructive and the usual presence of multiple synchronous lesions.

## 5 DIFFERENTIAL DIAGNOSES

As we have seen, the clinical and imaging presentation of this type of lesion can take two forms: a circumscribed and solitary expansive intradiploic cranial lesion or a lytic form.

The differential diagnosis by imaging is very varied and depends on whether we are dealing with a patient of pediatric age or an adult<sup>42</sup>.

In adult patients, lytic lesions may correspond to: multiple myeloma, Langerhans cell histiocytosis, inclusion cysts, Paget's disease, lesions related to hyperparathyroidism, among others<sup>42</sup>.

It is important to remember the possibility of normal images of the shell (variants of normality) that can simulate a lytic lesion such as parietal foramina or focal defects related to birth trauma.

Other less common lesions include: osteoid osteoma, aneurysmal bone cyst, giant cell tumor, fibrous dysplasia, osteogenic sarcomas, intraosseous meningiomas, lymphoma, hemangioendothelioma, dermoid tumor, intradiploic hematoma, or calcified cephalohematoma, in pediatric cases<sup>11,12,15-17,29,42,43</sup>.

The clinical difference between these lesions is not always simple and lies mainly in the analysis of the images, although there are no absolutely specific findings that allow an accurate diagnosis to be made.

In Table 2 the differential imaging characteristics of some of the lesions described are summarized.

## 6 TREATMENT

According to Heckl<sup>17</sup>, the first attempt to resect a cranial cavernous angioma was made by Ehrmann in 1847, but the patient died postoperatively. The first successful resection was performed

**Table 2.** Diferential diagnosis of some skull tumors.

Type of lesion	Clinical features	Imaging	Treatment
Dermoid cyst	Mass effect, Painless	MRI: hypointense on T1, Hyperintense in T2 and DWI	Surgical excision
Metastases	Asymptomatic, mass fast growing	CT: Osteolytic lesions. MRI: Inespecific pattern, ring enhancement	Surgical excision RTP
Low grade hemangioendothelioma	Local pain and rapidly worsening	MRI: hypointense on T1 and hyperintense on T2. Heterogeneous enhancement	Surgery, eventually radiation. Only radiation of surgery is not possible
Cephalocele	Ocurr in newborn	Bony defect with tissue herniation	Surgery
Intraosseous arachnoid cyst	asymptomatic	MRI: CSF signal	Surgery if aesthetic deformation
Cavernous angioma	Pain and mass efect	MRI: mixed low and high signal on T1, high signal on T2. Heterogeneous enhancement.	Surgery if symptomatic

CSF: Cerebrospinal fluid, RTP: radiotherapy.



by Pilcher in 1894, who performed the piecemeal resection of a cranial cavernoma, while Cushing in 1923 reported the first *en bloc* resection of a lesion of this type<sup>9,17</sup>.

The ideal treatment for these lesions is complete resection with healthy bone margins<sup>6,7,41</sup>. This ensures a high rate of healing and also reduces the risk of intraoperative bleeding<sup>11</sup>. Recurrence is very rare if it is resected with a good bone margin (0.5-1cm).

A detail to take into account is that there may be significant bleeding from dural vessels when the lesion is very bulky or when it alters the internal bone table<sup>42,43</sup>.

There are reports of treatment of cavernomas with curettage, but it has the risk of bleeding and recurrence<sup>9,17,22</sup>.

Radiation therapy has been used as an option in incomplete resections or recurrences<sup>11</sup>. It can limit the growth of the lesion but does not manage to heal them and therefore, it could be used in some very selected cases of extensive angiomas or "infiltrating" close to vascular structures<sup>6,29,44</sup>.

Preoperative embolization is also described in selected cases that are very large, invasive, or in which resection was attempted and could not be performed due to heavy bleeding, with the aim of reducing intraoperative bleeding<sup>17,29,43</sup>. Before embolization availability, cases of ligation of the external carotid artery to reduce intraoperative bleeding have been described<sup>9</sup>.

## REFERENCES

1. Tyagi DK, Balasubramaniam S, Sawant HV. Giant primary ossified cavernous hemangioma of the skull in an adult: A rare calvarial tumor. *J Neurosci Rural Pract.* 2011;2(2):174-7. <http://doi.org/10.4103/0976-3147.83587>. PMID:21897684.
2. Alexiou GA, Lampros M, Gavra MM, Vlachos N, Ydreos J, Boviatis EJ. Primary intraosseous cavernous hemangioma of the cranium: a systematic review of the literature. *World Neurosurg.* 2022;164:323-9. <http://doi.org/10.1016/j.wneu.2022.05.107>. PMID:35654328.
3. Costanzo R, Scalia G, Iacopino DG, Nicoletti G. Concomitant giant purely intradiploic cavernous haemangioma and multifocal neurotoxoplasmosis. *BMJ Case Rep.* 2022;15(11):e252451. <http://doi.org/10.1136/bcr-2022-252451>. PMID:36319034.
4. Nagamine K, Kanaya K, Miyairi Y, Ogiso Y, Shigeta H. Aggressive growing of the infantile cavernous hemangioma of the calvaria: a case report and review of literature. *Childs Nerv Syst.* 2021;37(1):319-23. <http://doi.org/10.1007/s00381-020-04678-4>. PMID:32435889.
5. Bteich F, Kassab C, El Hage G, Moussa R, Abadjian GA, Bou-Nassif R. Atypical presentation of parietal convexity dural-based cavernous hemangioma: a case report and review of literature. *World Neurosurg.* 2019;128:403-7. <http://doi.org/10.1016/j.wneu.2019.04.119>. PMID:31009776.
6. Yang Y, Guan J, Ma W, et al. Primary intraosseous cavernous hemangioma in the skull. *Medicine.* 2016;95(11):e3069. <http://doi.org/10.1097/MD.0000000000003069>. PMID:26986133.
7. Khanam H, Lipper MH, Wolff CL, Lopes MBS. Calvarial hemangiomas: report of two cases and review of the literature. *Surg Neurol.* 2001;55(1):63-7. [http://doi.org/10.1016/S0090-3019\(00\)00268-8](http://doi.org/10.1016/S0090-3019(00)00268-8). PMID:11248320.
8. Toynbee J. An account of two vascular tumours developed in the substance of bone. *Lancet.* 1845;2:676.
9. Kirchhoff D, Eggert HR, Agnoli A. Cavernous angiomas of the skull. *Neurochirurgia.* 1978;21(2):53-62. PMID:643148.
10. Fernández AM, Cabrera RN, Alfonso SC, Figueredo Méndez J, García Mirabal MM. Cavernous hemangioma in the frontal bone: presentation of a case and review of the literature. *Invest Medicoquir.* 2020;12(3):16.
11. Curcio A, Dimitri LMC, Copelli C, Gorgolione LP, Germano A, Catapano D. Intraosseous cavernous hemangioma of the neurocranium: a review of the literature. *Caspian J Neurol Sci.* 2023;9(2):108-19. <http://doi.org/10.32598/CJNS.9.33.400.1>.
12. Martínez-Lage JF, Torroba MA, Cuartero Pérez B, Almagro MJ, López López-Guerrero A, de la Rosa P. Cavernous hemangiomas of the cranial vault in infants: a case-based update. *Childs Nerv Syst.* 2010;26(7):861-5. <http://doi.org/10.1007/s00381-010-1151-9>. PMID:20405132.
13. Honda M, Toda K, Baba H, Yonekura M. Congenital cavernous angioma of the temporal bone: case report. *Surg Neurol.* 2003;59(2):120-3. [http://doi.org/10.1016/S0090-3019\(02\)00985-0](http://doi.org/10.1016/S0090-3019(02)00985-0). PMID:12648911.
14. Yucel E, Akkaya H, Gurkanlar D, Ergun T. Congenital cavernous hemangioma of the skull. *Turk Neurosurg.* 2011;21(4):645-7. PMID:22194130.
15. Davern MS, Lovell MA, Wilkinson CC. Cavernous hemangiomas of the pediatric calvaria. *Pediatr Neurosurg.* 2015;50(6):321-4. <http://doi.org/10.1159/000439281>. PMID:26488394.
16. Heckl S, Aschoff A, Kunze S. Cavernomas of the skull: review of the literature 1975–2000. *Neurosurg Rev.* 2002;25(1-2):56-62. <http://doi.org/10.1007/s101430100180>. PMID:11954766.
17. Liu H, Chang X, Shang H, Li F, Zhou H, Xue X. Diffuse cavernous hemangioma of the skull misdiagnosed as skull metastasis in breast cancer patient: one case report and literature review. *BMC Cancer.* 2019;19(1):172. <http://doi.org/10.1186/s12885-019-5341-x>. PMID:30803439.
18. Wyke BD. Primary hemangioma of skull: a rare cranial tumour. *AJR Am J Roentgenol.* 1946;61:302-16.
19. Liu JK, Burger PC, Harnsberger HR, Couldwell WT. Primary intraosseous skull base cavernous hemangioma. *Skull Base.*



- 2003;13(4):219-28. <http://doi.org/10.1055/s-2004-817698>. PMID:15912181.
20. Naama O, Gazzaz M, Akhaddar A, et al. Cavernous hemangioma of the skull: 3 case reports. *Surg Neurol.* 2008;70(6):654-9. <http://doi.org/10.1016/j.surneu.2007.05.052>. PMID:18207223.
21. Sthapit PR, Sayami G, Saiju R. Multiple cavernous haemangioma of orbit and cranium: a case report. *JNMA J Nepal Med Assoc.* 2021;59(233):74-6. PMID:34508450.
22. Gravbrot N, Brasiense LBC, Alswied A, Sun B, Lemole GM Jr. Multiple extra-axial cavernous hemangiomas: a rare entity. *World Neurosurg.* 2019;130(30):364-8. <http://doi.org/10.1016/j.wneu.2019.07.104>. PMID:31326639.
23. Xu P, Lan S, Liang Y, Xiao Q. Multiple cavernous hemangiomas of the skull with dural tail sign: a case report and literature review. *BMC Neurol.* 2013;13(1):155. <http://doi.org/10.1186/1471-2377-13-155>. PMID:24161077.
24. Han D, Kim S, Jung JH, Chang KH. Cavernous hemangioma of the mastoid antrum. *J Int Adv Otol.* 2024;20(4):372-4. <http://doi.org/10.5152/iao.2024.231171>. PMID:39162066.
25. Grob SR, Wolkow N, Jakobiec FA, Lefebvre DR. Osseous cavernous hemangioma of the superior orbital rim. *Orbit.* 2018;38(3):259. <http://doi.org/10.1080/01676830.2018.1509099>. PMID:30118611.
26. Nasser K, Hayashi N, Kurosaki K, et al. Intraosseous cavernous hemangioma of the frontal bone. *Neurol Med Chir.* 2007;47(11):506-8. <http://doi.org/10.2176/nmc.47.506>. PMID:18037805.
27. Pastore FS, De Caro GM, Faiola A, Mauriello A, Giuffrè R. Cavernous hemangioma of the parietal bone: case report and review of the literature. *Neurochirurgie.* 1999;45(4):312-5. PMID:10599060.
28. Ohta H, Tanazawa T, Osuka K, Ito Y, Fukatsu T. True aneurysms of the middle meningeal artery associated with cavernous hemangioma of the skull--case report. *Neurol Med Chir.* 1991;31(4):203-5. <http://doi.org/10.2176/nmc.31.203>. PMID:1720207.
29. Sasagawa Y, Akai T, Yamamoto K, et al. Multiple cavernous hemangiomas of the skull associated with hepatic lesions. *Case Report. Neurol Med Chir (Tokyo).* 2009;49(4):162-6. <http://doi.org/10.2176/nmc.49.162>. PMID:19398861.
30. WORLD HEALTH ORGANIZATION [Internet]. Soft tissue and bone tumours. 5th ed. Lyon: International Agency for Research on Cancer; 2020 [cited 2025 May 16]. (WHO Classification of Tumours; vol. 3). Available from: <https://publications.iarc.fr/588>
31. Czerniak B, Dorfman HD. Dorfman and Czerniak's bone tumors. Philadelphia: Elsevier Health Sciences; 2015.
32. Tortorelli I, Bellan E, Chiusole B, et al. Primary vascular tumors of bone: a comprehensive literature review on classification, diagnosis and treatment. *Crit Rev Oncol Hematol.* 2024;195:104268. <http://doi.org/10.1016/j.critrevonc.2024.104268>. PMID:38237880.
33. Oh J, Han SI, Lim SC. Intraosseous hemangioma with aneurysmal bone cyst-like changes of the hyoid bone: case report and literature review. *Medicine.* 2024;103(6):e37137. <http://doi.org/10.1097/MD.00000000000037137>. PMID:38335421.
34. Khodarahmi I, Alizai H, Chalian M, et al. Imaging spectrum of calvarial abnormalities. *Radiographics.* 2021;41(4):1144-63. <http://doi.org/10.1148/rg.2021200198>. PMID:34197249.
35. Kee TP, Liauw L, Sathiyamoorthy S, Lee HY, Tan GSL, Yu WY. Large solitary lytic skull vault lesions in adults: radiological review with pathological correlation. *Clin Imaging.* 2020;59(2):129-43. <http://doi.org/10.1016/j.clinimag.2019.10.011>. PMID:31816540.
36. Suzuki Y, Ikeda H, Matsumoto K. Neuroradiological features of intraosseous cavernous hemangioma – case report. *Neurol Med Chir.* 2001;41(5):279-282. <http://doi.org/10.2176/nmc.41.279>. PMID:11396309.
37. Mitra I, Duraiswamy M, Benning J, Joy HM. Imaging of focal calvarial lesions. *Clin Radiol.* 2016;71(4):389-98. <http://doi.org/10.1016/j.crad.2015.12.010>. PMID:26873626.
38. Bravo-Martinez A, Marrero-Gonzalez AP, Suleiman-Suleiman MN, Vicenty-Padilla JC, Trullenque-Martinez E. Radiologic features with pathologic correlation of an unusual large intraosseous skull cavernous hemangioma. *Am J Case Rep.* 2019;20:525-30. <http://doi.org/10.12659/AJCR.913414>. PMID:30988275.
39. Ilyas M, Shah SA, Gojwari T, Rafiq S, Ellahi I, Ganaie KH. Classic imaging features of calvarial hemangioma – a case report. *Egypt J Radiol Nucl Med.* 2018;49(3):663-5. <http://doi.org/10.1016/j.ejnm.2018.04.010>.
40. Mobbs RJ, Gollapudi PR, Fuller JW, Dahlstrom JE, Chandran NK. Intradiploic hematoma after skull fracture: case report and literature review. *Surg Neurol.* 2000;54(1):87-91. [http://doi.org/10.1016/S0090-3019\(00\)00263-9](http://doi.org/10.1016/S0090-3019(00)00263-9). PMID:11024513.
41. Murrone D, De Paulis D, Millimaggi DF, Del Maestro M, Galzio RJ. Cavernous hemangioma of the frontal bone: a case report. *J Med Case Reports.* 2014;8(1):121. <http://doi.org/10.1186/1752-1947-8-121>. PMID:24717076.
42. Hernández Borroto CE, Amado Donestévez A, Vaquer Fernández JE, Medrano Plana Y, Ruiz Martín M. Giant cavernous hemangioma of the cranial vault. Reporting a case. *Rev Neurol.* 2004;38(8):799-800. PMID:15122552.
43. Torii Y, Hosoya M, Hasebe N, et al. Resection of a large cavernous hemangioma following preoperative embolization in a child's temporal bone. *J Int Adv Otol.* 2021;17(3):269-74. <http://doi.org/10.5152/iao.2021.8755>. PMID:34100755.
44. Chung JH, Kim HJ, Kang HC, Kim IH, Lee JH. Long-term outcomes of radiotherapy for inoperable benign soft tissue tumors in the skull base or head. *Radiat Oncol J.* 2025;43(1):49-54. <http://doi.org/10.3857/roj.2024.00493>. PMID:40200657.

## CORRESPONDING AUTHOR

Fernando Martinez

E-mail: [fermartneuro@gmail.com](mailto:fermartneuro@gmail.com)

*Funding: none.*

*Conflict of interests: none.*