



Intramedullary abscess associated with intrathecal morphine pump: a case report

Absceso intramedular asociado a bomba intratecal de morfina: reporte de un caso

Giovanna Zambo Galafassi¹ 

Helvécio Neves Feitosa Filho² 

Saulo Barros Teixeira¹ 

Murilo Medeiros Alvarenga¹ 

Marcos Antônio Pereira do Rêgo¹ 

Dante Picciotti¹

Marco Túlio Sette dos Santos¹ 

Marco Prist Filho¹

Jorge Roberto Pagura¹ 

ABSTRACT

Introduction: Intramedullary abscesses are extremely rare, with less than 140 cases described in the literature. The prevalence is higher in children, and frequently associated with dermoid cysts and congenital malformations. They tend to develop in patients with systemic diseases leading to immunodeficiencies, such as diabetes mellitus, in patients with congenital abnormalities, adjacent spinal infection, or in use of intravenous drugs. **Case report:** Female patient, 48 years-old, was admitted with progressive paraplegia initiated one year ago. Multiple comorbidities, including Marfan syndrome, congenital femoral/hip malformation and bilateral visual deficit were found. She had an insertion of intrathecal morphine pump over five years ago because of chronic lower limb pain. On thoracolumbar magnetic resonance imaging, an irregular and infiltrating contrast-enhanced mass centered in the medullary canal was found. The lesion extended over 15 cm from T8 to L1. Microsurgical resection of the lesion was indicated. After myelotomy, multiple purulent foci were identified. The analysis of the collected material and morphine pump confirmed the presence of *Serratia marcescens*. Cefepime and vancomycin were initiated according to the infectologist's orientation, with a plan to keep treatment for 6 weeks. Although the patient maintained neurological deficits after surgery, there was an improvement in pain control. However, the patient progressed to death 30 days after surgery due to cardiorespiratory arrest, probably secondary to cardiac complications. **Discussion:** Intramedullary spinal cord abscess (ISCA) is a rare neurological entity in spinal cord infection, with more than 140 cases described in the literature since its first description in 1830. These infections are traditionally correlated with high morbidity and mortality. There is a relationship between comorbidities and increased incidence of ISCA, including immunosuppression, diabetes, intravenous drug use, alcoholism, infective endocarditis, genitourinary infections, lung disease, and trauma. *Escherichia coli*, *Staphylococcus aureus*, and *Mycobacterium tuberculosis* are the most reported agents. We found another case in the literature featuring *Serratia marcescens*. Both cases involved critical, and severe intramedullary abscesses that demanded aggressive interventions, such as laminectomy and surgical drainage. We also found another case related to intrathecal morphine pump, raising concerns regarding possible complications of this device. **Conclusion:** The presence of intramedullary abscesses caused by intrathecal morphine pumps reveals significant insights into complications of such devices, emphasizing the need for diligent monitoring and management due to severe neurological issues and infections linked to the pumps.

Keywords: neuroinfection; spine; abscess.

¹Faculdade de Medicina do ABC, Departamento de Neurocirurgia, Santo André, SP, Brasil.

²Universidade de Fortaleza, Faculdade de Medicina, Fortaleza, CE, Brasil.

Received Mar 19, 2025

Accepted Mar 23, 2025



This is an Open Access article distributed under the terms of the [Creative Commons Attribution](https://creativecommons.org/licenses/by/4.0/) license (<https://creativecommons.org/licenses/by/4.0/>), which permits unrestricted use, distribution, and reproduction in any medium, provided the original work is properly cited.

RESUMEN

Introducción: Los abscesos intramedulares son extremadamente raros, con menos de 140 casos descritos en la literatura. Tienen una mayor prevalencia en niños, a menudo asociados con quistes dermoides y malformaciones congénitas. Suelen desarrollarse en pacientes con enfermedades sistémicas que conducen a inmunodeficiencia, como la diabetes mellitus; en pacientes con anomalías congénitas; en infecciones espinales adyacentes; o en el uso de drogas intravenosas. **Informe de caso:** Paciente femenina de 48 años, admitida con paraplejía progresiva que comenzó hace un año. Presentaba múltiples comorbilidades, incluyendo síndrome de Marfan, malformación congénita de fémur/caderas y déficit visual bilateral. Había recibido la inserción de una bomba intratecal de morfina hace más de cinco años debido a dolor crónico en las extremidades inferiores. En la resonancia magnética toracolumbar, se encontró una masa irregular e infiltrante, con captación de contraste, centrada en el canal medular. La lesión se extendía más de 15 cm desde T8 hasta L1. Se indicó la resección microquirúrgica de la lesión. Tras la mielotomía, se encontraron múltiples focos purulentos. El análisis del material recolectado y de la bomba de morfina confirmó la presencia de *Serratia marcescens*. Se iniciaron cefepima y vancomicina según la orientación del infectólogo, con un plan de mantener el tratamiento durante 6 semanas. La paciente mantuvo déficits neurológicos tras la cirugía; sin embargo, hubo una mejora en el control del dolor. No obstante, la paciente falleció 30 días después de la cirugía debido a un paro cardiorrespiratorio, probablemente secundario a complicaciones cardíacas. **Discusión:** El absceso intramedular de la médula espinal (AIME) es una entidad neurológica rara en las infecciones de la médula espinal, con más de 140 casos descritos en la literatura desde su primera descripción en 1830. Estas infecciones tradicionalmente se correlacionan con alta morbilidad y mortalidad. Existe una relación entre las comorbilidades y el aumento de la incidencia de AIME, incluyendo inmunosupresión, diabetes, uso de drogas intravenosas, alcoholismo, endocarditis infecciosa, infecciones genitourinarias, enfermedades pulmonares y trauma. *Escherichia coli*, *Staphylococcus aureus* y *Mycobacterium tuberculosis* son los agentes más reportados. Encontramos otro caso en la literatura que presenta *Serratia marcescens*; ambos casos involucraron abscesos intramedulares críticos y severos que requirieron intervenciones agresivas como laminectomía y drenaje quirúrgico. También encontramos otro caso relacionado con una bomba intratecal de morfina, lo que plantea la preocupación sobre las posibles complicaciones de este dispositivo. **Conclusión:** La presencia de un absceso intramedular causado por una bomba intratecal de morfina revela importantes conocimientos sobre las complicaciones de dichos dispositivos, enfatizando la necesidad de un monitoreo y manejo diligentes debido a los graves problemas neurológicos e infecciones vinculadas a las bombas.

Palabras clave: neuroinfección; columna vertebral; absceso.

1 INTRODUCTION

Intramedullary abscesses are extremely rare, with less than 140 cases described in the literature. Higher prevalence was found in children, frequently associated with dermoid cysts and congenital malformations. They tend to develop in patients with systemic diseases that lead to immunodeficiency, such as diabetes mellitus, patients with congenital abnormalities, adjacent spinal infection, or in use of intravenous drugs. They might be misdiagnosed as intramedullary tumors when correct diagnosis is made during surgery.

2 METHODS

We describe a case operated on in our service and also performed a literature review regarding this rare disease.

For the literature review, we included papers that met the criteria of observational studies, reviews, or case reports, studies in humans and the presence of intramedullary abscesses. We excluded non-English papers. We searched the PubMed, Cochrane, Web of Science, and Embase databases using terms associated with ("intramedullary abscess"). Observational studies and case series comprise our sample due to the lack of studies in the literature. The references from all included studies were manually screened.

3 CASE REPORT

Female patient, 48 years-old, admitted with progressive paraplegia initiated one year ago. The patient also developed sensibility dysfunction on her lower limbs and severe urinary retention over the same period.

She had multiple comorbidities, including Marfan syndrome, congenital femoral/hip malformation, and bilateral visual deficit. She also had a medical history of multiple treatments for chronic pain in the lower limbs, including morphine pump insertion, over five years. Due to loss of health insurance, the pump was inactive for one year.

Neurological exam on admission showed spastic paraplegia, bilateral exhaustible clonus, bilateral Babinski sign, and normal osteotendinous reflexes. Anesthesia was administered at the T10 level.

On thoracolumbar magnetic resonance imaging was found an irregular and infiltrating contrast-enhanced mass centered in the medullary canal invading the adjacent spinal nerve roots. The lesion extended over 15 cm from T8 to L1. The medullary canal was enlarged and the medullary parenchyma was atrophic (Figure 1).

Microsurgical resection of the lesion was indicated. We performed T10-L1 laminectomy, flavectomy, and durotomy at the same level. After durotomy, multiple yellow lesions were seen through the spine. After myelotomy, purulent secretions were immediately drained. A sample of the material was collected for analysis. After drainage of all visible purulent foci, hermetic closing was performed. Finally, the morphine pump located in the abdominal region was removed (Figures 2 and 3).

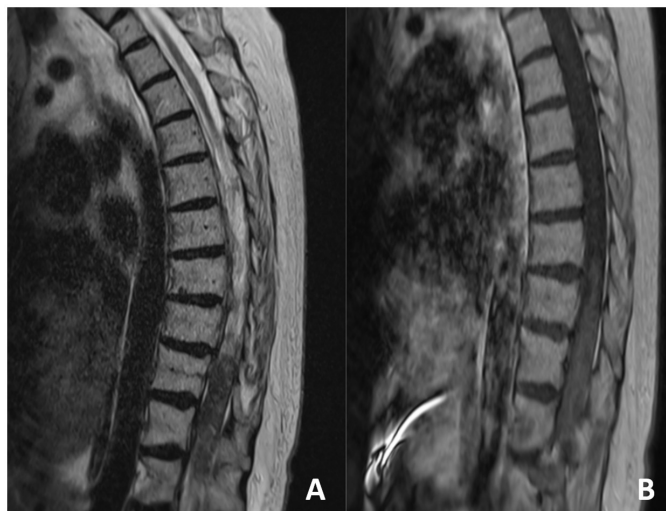

Figure 1. Magnetic resonance imaging of thoracic spine. (A) T2, showing hypointense infiltrating contrast-mass centered in the medullary canal between T8 and L1; (B) T1. Note the presence of the intrathecal pump catheter.

The analysis of the collected material confirmed the presence of *Serratia marcescens*. Cefepime and Vancomycin were initiated according to the infectologist's instructions, with a plan to keep treatment for 6 weeks.

The patient maintained neurological deficits, but there was an improvement in pain control. Unfortunately, 30 days after surgery, the patient presented with cardiorespiratory arrest, probably due to cardiac complications, and progressed to death.

4 DISCUSSION

Intramedullary spinal cord abscess (ISCA) is a rare neurological entity in spinal cord infection with more than 140 cases described in the literature since its first description by Hart in 1830. These

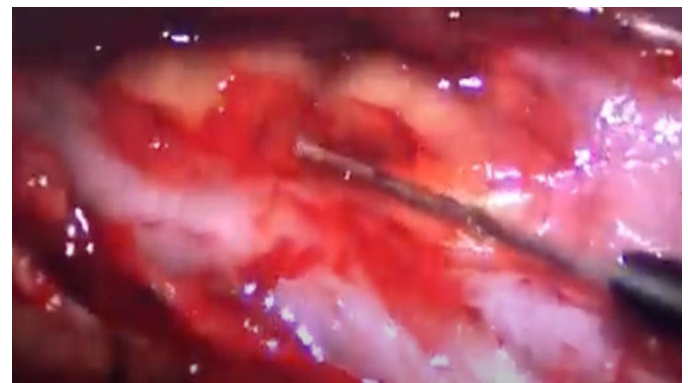

Figure 2. Microsurgical view presenting purulent foci over the medulla.

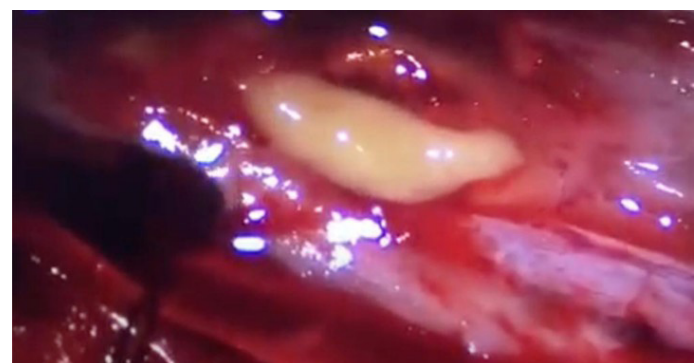

Figure 3. Microsurgical view presenting purulent secretions after myelotomy.

infections are traditionally correlated with high morbidity and mortality¹. They are located in different regions of the spinal cord. Review studies quantitatively addressed these locations, with the review by Jabbar et al.² finding 25 abscesses (35.71%) mainly involving the cervical cord, 19 (27.14%) the thoracic cord, 3 (4.2%) the lumbar cord, 8 (11.42%) cervical to thoracic, 8 (11.42%) thoracic to lumbar, 1 (1.42%) lumbar to sacral and holocord, 2 (2.85%) the conus, and 4 cases presented multiple abscesses. Byrne et al.³ found that 36% of intramedullary abscesses primarily involved the cervical cord, 36% the conus, and 29% the thoracic cord, while the lower thoracic and lumbar segments were the common sites for midline congenital defects. The locations between the thoracic and lumbar regions have a higher percentage of worse prognosis⁴.

In terms of etiology, these can be divided into four groups: bacterial and fungal infections, penetrating trauma to the spinal cord, congenital dural sinuses, and chronic tuberculosis². *Escherichia coli*, *Staphylococcus aureus*, and *Mycobacterium tuberculosis* were the most frequently reported agents. Gram-positive bacteria were recorded in 30% of cases, and gram-negative in 20.5%⁴.

Furthermore, there was a relationship between comorbidities and increased incidence of ISCA, including immunosuppression, diabetes, intravenous drug use, alcoholism, infective endocarditis, genitourinary infections, lung disease, and trauma⁵⁻¹³.

Regarding the adult population, Harrold et al.¹⁴ compared the outcomes of adult patients with ISCA, and noted that among patients who underwent surgical intervention, surgery within 24 hours of diagnosis was associated with a greater likelihood of being outpatient in follow-up and experiencing any clinical improvement compared with surgery after 24 hours. There was no significant association between surgery within 24 hours and the likelihood of death and other factors, such as sex and age¹⁴.

In contrast, intramedullary abscesses were associated with previous surgical procedures, as shown in previously published cases^{8,9,12,15-17}.

Notably, the coexistence of neurofibromatosis type 1 and the presence of multiple comorbidities, including Marfan syndrome in our patient, suggest a fertile ground for the development of complications¹⁸. Clinically, our patient manifested progressive paraplegia, sensory dysfunction in the lower limbs, and severe

urinary retention — a presentation consistent with the most severe cases documented, as well as in the cases of Mohindra and Thakar.

The use of specific antibiotic agents, such as Cefepime and Vancomycin, reflects a protocol similar to that of Morandi, who used Cefotaxime, Amoxicillin, and Vancomycin, indicating a standardized approach for these cases. However, outcomes vary significantly. The majority of documented patients recovered neurological function, in contrast to the fatal outcome of our patient, whose death from cardiorespiratory complications highlights the potential severity of these cases and underscores the exceptionality of the Mohindra case, where the patient also died due to rapid disease progression.

The cases diverged markedly in personal and medical contexts. The female patient experienced delayed treatment due to socioeconomic barriers like loss of health insurance, resulting in her death shortly after surgery, whereas the male patient who received prompt treatment significantly recovered, demonstrating the importance of timely, tailored surgical interventions.

Additionally, comparing our case to another in the literature featuring *Serratia marcescens*, both cases involved critical, severe intramedullary abscesses that demanded aggressive interventions like laminectomy and targeted antibiotics, underscoring the urgency of medical action¹⁸. Finally, the outcomes varied greatly, our case — a patient with multiple comorbidities and a deactivated pump — leading to fatal outcomes, whereas the second case involved a patient with neurofibromatosis type 1 with postoperative improvement, illustrating how patient histories and symptom acuity influence clinical outcomes.

5 CONCLUSION

Intramedullary abscesses are rare and a severe disease that should be considered in patients with progressive motor deficit, multiple comorbidities and intramedullary lesions. Furthermore, patients in use of intrathecal morphine pump should be closely watched for this possible complication. Immediate intervention, generally by surgical drainage, is mandatory for satisfactory results.

REFERENCES

- Hood B, Wolfe SQ, Trivedi RA, Rajadhyaksha C, Green B. Intramedullary abscess of the cervical spinal cord in an otherwise healthy man. *World Neurosurg.* 2011;76(3-4):361.e15-9. <http://doi.org/10.1016/j.wneu.2010.01.013>. PMID:21986440.
- Jabbar R, Szmyd B, Jankowski J, et al. Intramedullary spinal cord abscess with concomitant spinal degenerative diseases: a case report and systematic literature review. *J Clin Med.* 2022;11(17):5148. <http://doi.org/10.3390/jcm11175148>. PMID:36079075.
- Byrne RW, Von Roenn KA, Whisler WW. Intramedullary abscess: a report of two cases and a review of the literature. *Neurosurgery.* 1994;35(2):321-6. <http://doi.org/10.1227/00006123-199408000-00023>. PMID:7969844.
- Satyadev N, Moore C, Khunkhun SK, et al. Intramedullary spinal cord abscess management: case series, operative video, and systematic review. *World Neurosurg.* 2023;174:205-212.e6. <http://doi.org/10.1016/j.wneu.2023.03.013>. PMID:36898628.
- Arnáiz-García ME, González-Santos JM, López-Rodríguez J, Dalmau-Sorli MJ, Bueno-Codoñer M, Arévalo-Abascal A. Intramedullary cervical abscess in the setting of aortic valve endocarditis. *Asian Cardiovasc Thorac Ann.* 2015;23(1):64-6. <http://doi.org/10.1177/0218492313495861>. PMID:24887857.
- Babu R, Jafar JJ, Huang PP, Budzilovich GN, Ransohoff J. Intramedullary abscess associated with a spinal cord ependymoma: case report. *Neurosurgery.* 1992;30(1):121-4. <http://doi.org/10.1227/00006123-199201000-00023>. PMID:1738441.
- Silva PS, Souza Loduca RD. Intramedullary spinal cord abscess as complication of lumbar puncture: a case-based update. *Childs Nerv Syst.* 2013;29(7):1061-8. <http://doi.org/10.1007/s00381-013-2093-9>. PMID:23559394.
- Maurice-Williams RS, Pamphilon D, Coakham HB. Intramedullary abscess: a rare complication of spinal dysraphism. *J Neurol Neurosurg Psychiatry.* 1980;43(11):1045-8. <http://doi.org/10.1136/jnnp.43.11.1045>. PMID:7003066.
- Mohindra S, Gupta R, Mathuriya SN, Radotra BD. Intramedullary abscess in association with tumor at the conus medullaris: report of two cases. *J Neurosurg Spine.* 2007;6(4):350-3. <http://doi.org/10.3171/spi.2007.6.4.11>. PMID:17436925.
- Sverzut JM, Laval C, Smadja P, Gigaudo M, Sevely A, Manelfe C. Spinal cord abscess in a heroin addict: case report. *Neuroradiology.* 1998;40(7):455-8. <http://doi.org/10.1007/s002340050623>. PMID:9730347.
- Takebe N, Iwasaki K, Hashikata H, Toda H. Intramedullary spinal cord abscess and subsequent granuloma formation: a rare complication of vertebral osteomyelitis detected by diffusion-weighted magnetic resonance imaging. *Neurosurg Focus.* 2014;37(2):E12. <http://doi.org/10.3171/2014.6.FOCUS14141>. PMID:25081961.
- Thakar S, Rao A, Mohan D, Hegde A. Metachronous occurrence of an intramedullary abscess following radical excision of a cervical intramedullary pilocytic astrocytoma. *Neurol India.* 2013;61(3):322-4. <http://doi.org/10.4103/0028-3886.115089>. PMID:23860166.
- Ueno T, Nishijima H, Funamizu Y, et al. Intramedullary spinal cord abscess associated with spinal dural arteriovenous fistula. *J Neurol Sci.* 2016;368:94-6. <http://doi.org/10.1016/j.jns.2016.06.068>. PMID:27538608.
- Harrold GK, Ali AS, Berkowitz AL, Bhattacharyya S. Clinical features and diagnosis of intramedullary spinal cord abscess in adults: a systematic. *Neurology.* 2023;101(8):e836-44. <http://doi.org/10.1212/WNL.0000000000207515>. PMID:37400243.
- Vadera S, Harrop JS, Sharan AD. Intrathecal granuloma and intramedullary abscess associated with an intrathecal morphine pump. *Neuromodulation.* 2007;10(1):6-11. <http://doi.org/10.1111/j.1525-1403.2007.00081.x>. PMID:22151806.
- Hardwidge C, Palsingh J, Williams B. Pyomyelia: an intramedullary spinal abscess complicating lumbar lipoma with spina bifida. *Br J Neurosurg.* 1993;7(4):419-22. <http://doi.org/10.3109/02688699309103498>. PMID:8216914.
- Morandi X, Mercier P, Fournier HD, Brassier G. Dermal sinus and intramedullary spinal cord abscess: report of two cases and review of the literature. *Childs Nerv Syst.* 1999;15(4):202-6. <http://doi.org/10.1007/s003810050370>. PMID:10361972.
- Valeri AL, Alayli A, Gordon J, Lockard G, Tran ND. Intramedullary spinal cord abscess as postoperative complication: a case report. *Surg Neurol Int.* 2024;15:147. http://doi.org/10.25259/SNI_176_2023. PMID:38741995.

CORRESPONDING AUTHOR

Giovanna Zambo Galafassi
 Email: giovannagalafassi@gmail.com

Funding: none.

Conflict of interests: none.